

## **Liv.52 Protection Against Cadmium-induced Histomorphological Changes in Mice Spleen, Duodenum and Small Intestine**

**Rathore, H.S. and Miss. Hema Rawat**

School of Studies in Zoology, Vikram University, Ujjain, India.

### **ABSTRACT**

*20 ppm of cadmium chloride (CdCl<sub>2</sub>) 10 ml solution mixed in food was fed to one group of mice for 30 days. The second group of mice received CdCl<sub>2</sub> and 5 ml of Liv.52 syrup for 30 days. The third group acted as controls. Mice of all three groups were killed on the 31<sup>st</sup> day. Prior to fixation in Bouin's fluid the spleen was measured in each group for its length and width. Fixed spleen was cut at 6  $\mu$  and stained in Delafield's hematoxylin and eosin. Statistical analysis of the length and width of spleens among different groups revealed that CdCl<sub>2</sub> feeding caused splenomegaly, but when Liv.52 was administered along with CdCl<sub>2</sub>, the spleen size remained normal. Histology of the spleen revealed that CdCl<sub>2</sub>, ingestion caused congestion of sinuses and hyperplasia. When Liv.52 was administered along with CdCl<sub>2</sub> the spleen showed almost normal histology.*

*Likewise, after sacrifice the mice guts were fixed in Bouin's fluid. Fixed duodenum and small intestine were cut at 6  $\mu$  and stained in Delafield's hematoxylin. Microscopic observations of the slides revealed mild to severe histopathological changes in the villi of the duodenum and small intestine. But the administration of Liv.52 protected them against CdCl<sub>2</sub> toxicity.*

*The results suggest that Liv.52 protects mice spleen, duodenum and intestine against cadmium intoxication. The possible modes of the protective action of Liv.52 are discussed.*

### **INTRODUCTION**

Cadmium is a well-known heavy metal pollutant (Nriagu, 1980), which enters the human body through food (Schroeder *et al.*, 1967; Yamagata and Shigematsu, 1970; Bruhn and Frank, 1974; Sharma, 1980; Food and Drug Administration, 1975). Its inhalation either as oxide or by smoking (Piscator, 1986) affects the haematopoietic system. Mild anaemia and decreased hemoglobin and hepatogloin levels were observed in factory workers who had high Cd levels in their blood (Nicaud *et al.*, 1942; Friberg, 1950; Tsuchiya, 1967; Berlin and Piscator, 1961; Axelsson and Piscator, 1966). Itai-Itai disease patients show non-chronic anaemia (Shinoda *et al.*, 1977). Cadmium affects the liver and kidney primarily, but also damages the gut because after dietary exposure a portion of cadmium is absorbed into the mucosal cells of the small intestine, while the non-absorbed portion is excreted into feces (Hietanen 1980).

Liv.52 is a herbal remedy which primarily corrects liver dysfunction and protects the liver against hepatotoxins like paracetamol (Mazumdar and Kulkarni, 1978), anticancer drugs (Vaidya, 1978), antibiotics (The Himalaya Drug Company report, 1967), oral contraceptives (Khuteta, 1978), alcohol (Damle and Kulkarni, 1973, Patrao, 1957) allyl alcohol (Joglekar and Balwani, 1969), carbon tetrachloride (Saxena and Garg, 1981) and heavy metals like Cd (Rathore and Verma, 1986). In the past, several workers have observed that Liv.52 could also help in raising the haemoglobin

percentage which was lowered following liver enlargement, liver cirrhosis, malnutrition, proteinaemia, fat malabsorption and anaemia associated with primary tuberculosis (Dayal *et al.*, 1970; Pai, *et al.*, 1974, Patney *et al.*, 1976, Sharma *et al.*, 1975). Recently it has been reported that Liv.52 afforded protection against Cd-induced liver dysfunction and histopathological changes in mice kidney (Rathore and Verma, 1986; Rathore, 1986). Again, Nath (1986) has reported Cd-concentration in common Indian food items. Malnutrition, a low protein diet, low calcium, low selenium, low iron and hypervitaminosis of Vit. C and Vit. D and low zinc in the diet enhance cadmium uptake (Nath, 1986). Unfortunately, malnutrition and malabsorption syndrome is common in Asian countries including India. It was, therefore, decided to test the ability of Liv.52 to protect mice spleen duodenum and small intestine against the toxic effects of cadmium.

## METHODS

### *Experimental*

Four-month-old Swiss albino male mice obtained from the Biological Products Division, Veterinary College, Mhow (M.P.) were used. The mice were placed in propylene cages and given water and food *ad libitum*.

Liv.52 syrup used in our study contained the following composition:

Each 2.5 ml of Liv.52 syrup contains:

Exts. <i>Capparis spinosa</i>	17 mg
<i>Cichorium intybus</i>	17 mg
<i>Solanum nigrum</i>	8 mg
<i>Cassia occidentalis</i>	4 mg
<i>Terminalia arjuna</i>	8 mg
<i>Achillea millefolium</i>	4 mg
<i>Tamarix gallica</i>	4 mg

Processed in *Eclipta alba*, *Phyllanthus niruri*, *Boerhaavia diffusa*, *Tinospora cordifolia*, *Berberis aristat*, *Raphanus sativus*, *Phyllanthus emblica*, *Plumbaga zylanica*, *Emberlia ribes*, *Terminalia chebula* and *Fumaria officinalis*.

### *Treatment*

The mice were divided into three large groups and received the following:

- Group A Liv.52 syrup 5 ml + cadmium chloride 10 ml of 20 ppm solution mixed with 50 g of food.
- Group B Cadmium chloride 10 ml of 20 ppm solution mixed with 50 g of food
- Group C Standard food only 50 g.

In each group 8 mice were used and the experiment was done three times. Mice of all the groups were killed on the 31<sup>st</sup> day. Prior to fixation in Bouin's fluid, the spleen was measured in each group for its length and width. Fixed spleen was cut at 6  $\mu$  and stained in Delafield's hematoxylin and eosin. Likewise their guts were fixed in Bouin's fluid. Fixed duodenum and small intestine were also cut at 6  $\mu$  and stained in Delafield's hematoxylin and eosin.

Observations of the permanent slides form the basis of the present results.

## RESULTS AND DISCUSSION

### Spleen

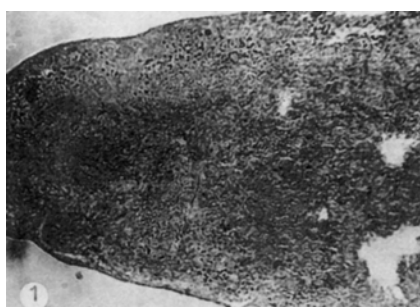
*Morphology:* Following CdCl<sub>2</sub> administration, their spleens showed enlargement i.e. there was significant increase in the length and width of the spleen (55% and 61% respectively) as compared to the controls. When CdCl<sub>2</sub> plus Liv.52 was administered to mice along with food, the spleen showed no difference in length and width, thus indicating normal size and shape. See the Table and also Fig. 1.

<b>Table:</b> Effect of cadmium chloride alone and in combination with Liv.52 on the morphology of mice spleen		
Treatment	Length (mm)	Width (mm)
Controls	16.16 ± 0.94	3.83 ± 1.00
CdCl <sub>2</sub> group	25.16 ± 0.54*	6.17 ± 0.02*
CdCl <sub>2</sub> plus Liv.52 group	16.83 ± 1.30	4.33 ± 0.13

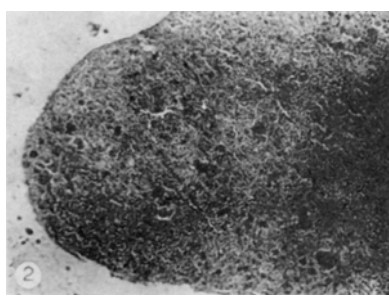
\*Significant difference at 5% level of significance using Student's 't' test.

*Histology:* In controls, mice spleen showed normal structure of the capsule; the trabeculi were normal sinuses were well differentiated and the pulp was well organized (Fig.1). When CdCl<sub>2</sub> was fed to mice along with food, the spleen showed sinus congestion. The pulp was organized but at places dead cells were seen. In the pulp most of the cells were swollen (Fig.2). Histology of the mice fed on CdCl<sub>2</sub> plus Liv.52 along with food showed normal capsule and trabeculi but the pulp was diffused. Sinuses were clear at many places (Fig.3).


**PLATE I: Photomicrographs of mice spleen fixed with Bouin's hematoxylin and eosin preparation**



**Fig. 1:** Transverse section (TS) spleen, controls, showing normal capsule, trabeculi and clear sinuses (100 X)



**Fig. 2:** TS spleen following CdCl<sub>2</sub> feeding showing congestion of sinuses (100 X)



**Fig. 3:** TS spleen following CdCl<sub>2</sub> + Liv.52 feeding showing almost normal structure, sinuses are clear (100 X)

### Duodenum and small intestine

Similarly, in controls, histology of the duodenum and the small intestine showed normal structure. The villi were long, showing organized epithelial cells. No pathological sign was evident (Figs.4 and 5).

Cadmium chloride feeding to mice affected their duodenal and small intestinal histology. The duodenum showed thin villi damaged at their tips due to death of epithelial cells (Figs. 6 and 7). CdCl<sub>2</sub> feeding also affected the villi in the small intestine, which showed broad villi with ill defined cytoplasmic boundaries indicating early necrosis (Figs.12 and 13). Also, in addition to early necrosis, advance necrosis was evident, as very low and fused villi forming a 'bunch' were seen (Figs. 16 and 17). Many such villi showed atrophy at their tips and even fully dead villi were also seen (Figs.14 and 15).

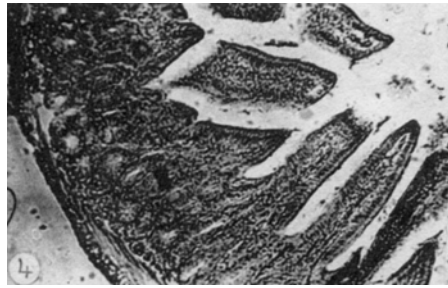
When CdCl<sub>2</sub> plus Liv.52 was fed to the mice, histology of the duodenum showed that the height of their villi was almost like that of controls (Figs.6 and 7). Early necrosis was seen only in a few sections. Histology of intestine showed thin and long villi. Epithelial cells showed distinct nuclei. Only a few villi showed fusion at tips (Fig.18 and 19). In general, histology of the duodenum and intestine in this group was better than what was seen in the Cd fed group. The results suggest that Liv.52 protects against cadmium induced histopathological changes in mice duodenum and small intestine.

#### ***Effect on the spleen***

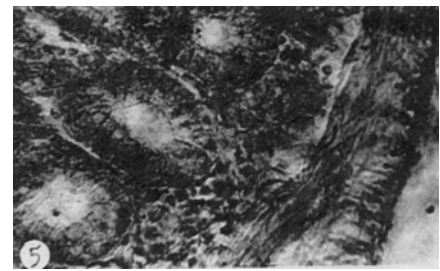
The results show that following Cd ingestion there occurred

splenomegaly and hyperplasia. The findings are in conformity with the previous reports. (Wilson *et al.*, 1941; Raymonds *et al.*, 1976). Results also show that when Liv.52 was administered along with Cd in the food, no change in the histomorphology of the spleen was observed. This suggests a protective effect of Liv.52 against Cd toxicity on the spleen. Two such reports have already appeared which suggest that Liv.52 can prevent splenomegaly. Saini *et al.*, (1984) have reported that following gamma irradiation there was significant enlargement of the spleen in mice, but following Liv.52 therapy it resumed normal size and shape. In another report Saini *et al.*, (1985) reported the radioprotective role of Liv.52 on the peripheral blood of Swiss albino mice, but these authors could not explain the exact mode of action of Liv.52. But possible modes of action will be postulated later in the discussion.

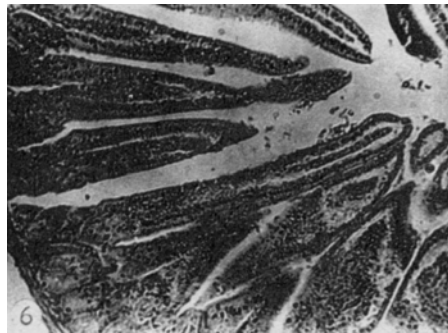
#### **PLATE II: Photomicrographs of mice gut fixed with Bouin's hematoxylin and eosin preparation**



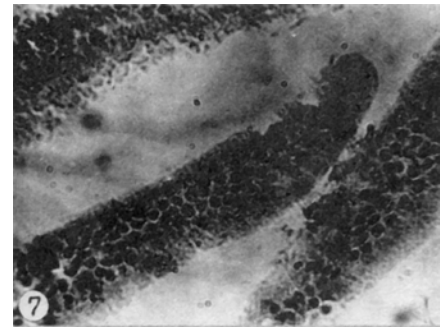
**Fig. 4:** TS duodenum controls, showing normal histology: villi are well differentiated, Brunner's glands are normal (100 X)



**Fig. 5:** Magnified view of previous figure to show normal duodenal histology (400 X)



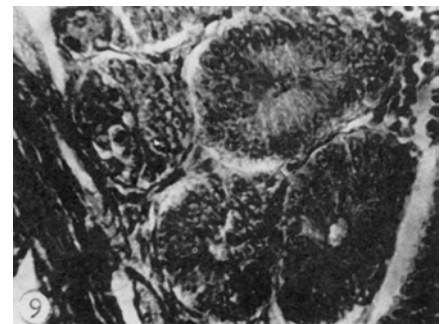
**Fig. 6:** TS duodenum following CdCl<sub>2</sub> feeding showing thin and long villi damaged at their tips



**Fig. 7:** Magnified view of the previous figure to show tips of damaged villi due to death of epithelial cells (400 X)



**Fig. 8:** TS duodenum following CdCl<sub>2</sub> + Liv.52 feeding showing normal height of villi (100 X)



**Fig. 9:** Magnified view of the previous figure to show localized early necrosis of Brunner's gland and at the base of villi

## Effect on the duodenum and small intestine

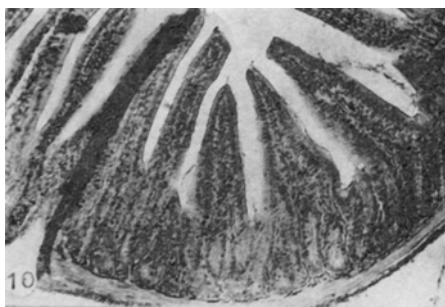Present results show that epithelial cells of the duodenal and intestinal mucosa were damaged following Cd ingestion. This pathological observation is in conformity with the earlier reports of Valberg *et al.*, 1977; Richardson and Fox, 1974; Riihimaki, 1972.

It was also evident that when Liv.52 was administered along with Cd to mice, their duodenal and intestinal histology appeared almost normal like that in control animals. This indicates that Liv.52 could afford protection to the gut against the toxic effects of cadmium. This finding gets support from a solitary report made by Tripathi *et al.*, (1977), who studied the effects of Liv.52 in thirty cases of malabsorption. In all

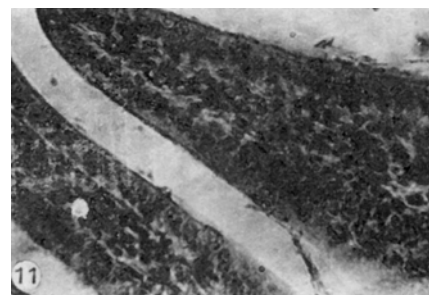
types of malabsorption histological changes in the mucosa of the entire gastrointestinal tract are reported including atrophic changes in the villi of the jejunum, which leads to malabsorption. These workers have reported that patients showed fusion of the villi along with broadening and shortening before therapy, which became normal in appearance following Liv.52 administration. At the moment, it is not possible to pinpoint how Liv.52 could present the toxic effects of cadmium. But possible pathways through which Liv.52 could have afforded protection are now described.

Cadmium has a very high affinity for cellular membranes, hence it binds with them and damages them (Taere *et al.*, 1977). It has been suggested that heavy metals like mercury and cadmium may

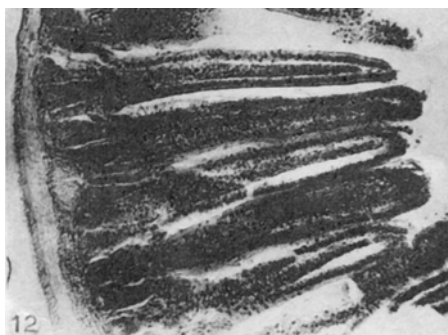
### PLATE III: Photomicrographs of mice gut fixed with Bouin's hematoxylin and eosin preparation



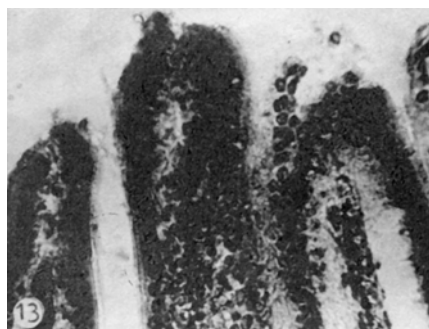
**Fig. 10:** TS intestine, control, showing normal histology (100 X)



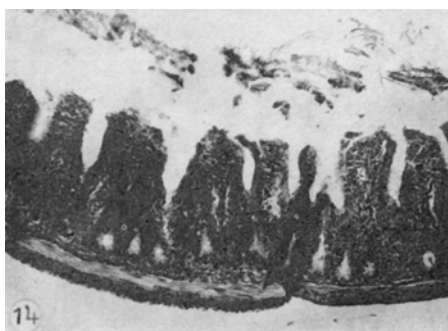
**Fig. 11:** Magnified view of previous figure to show healthy pointed villi (400 X)



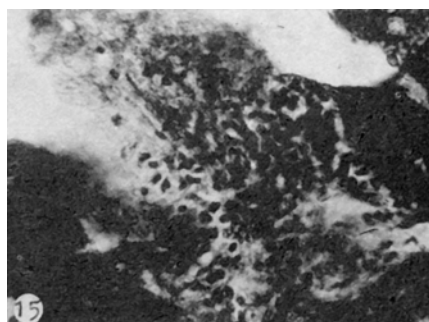
**Fig. 12:** TS intestine following CdCl<sub>2</sub> feeding to show thin and long villi. Cytoplasmic boundaries are not distinct due to early epithelial necrosis (100 X)



**Fig. 13:** Magnified view of the previous figure to show tips of villi undergoing degeneration (400 X)



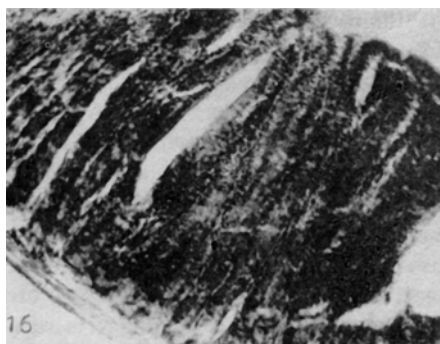
**Fig. 14:** TS intestine following CdCl<sub>2</sub> feeding to show very low and fused villi necrosed at their tips (100 X)



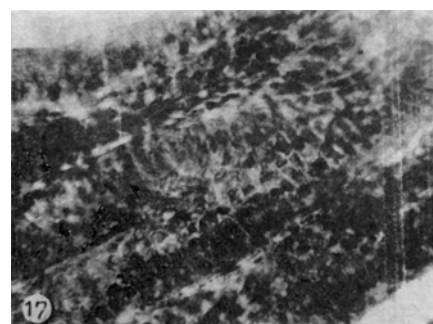
**Fig. 15:** Magnified view of previous figure to show low necrosed (dead) villi (400 X)

exert their toxic effects by causing lesions in cell membranes and subsequent altered permeability resulting from lipid peroxidation (Kinter and Pritchard, 1977). An enzyme glutathione peroxidase protects biomembranes against lipid peroxidation induced damage. Cadmium exposure causes a significant lowering in this enzyme in the kidney and intestinal mucosa (Kaur, 1982). Liv.52 is known to protect cellular membranes by lowering lipid peroxidation (Saxena *et al.*, 1980; Saxena and Garg, 1981).

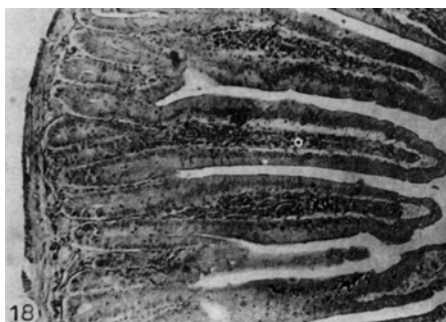**PLATE IV: Photomicrographs of mice gut fixed with Bouin's hematoxylin and eosin preparation**



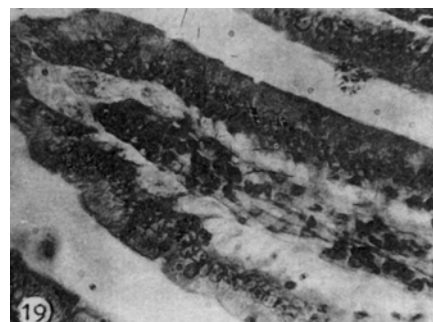
**Fig. 16:** TS intestine following CdCl<sub>2</sub> feeding showing broad villi fused lengthwise. Early necrosis evident (100 X)



**Fig. 17:** Magnified view of the previous figure to show fusion of villi; early necrosis can also be seen (400 X)



**Fig. 18:** TS intestine following CdCl<sub>2</sub> + Liv.52 feeding showing almost normal histology like controls (See Fig. 7) (400 X)



**Fig. 19:** Magnified view of the previous figure to show almost normal villi (See Fig. 8) (400 X)

Also a large quantity of Cd is stored in the erythrocytes as Cd-metallothionein complex (Nordberg *et al.*, 1971; Garty *et al.*, 1986) and haemolysis releases Cd from the erythrocytes (Piscator and Axelsson, 1970). If Liv.52 protects cell membranes, haemolysis can be prevented without further damage to blood cells. This explanation is, however, speculative for the time being.

Cadmium lowers activity of the zinc containing enzymes like carboxypeptidase (Coleman and Vallee, 1960). It has been reported that cadmium lowers the activity of alkaline phosphatase and leucine amino-peptidase in the intestine (Sastri and Subadra, 1985; Phillipotts *et al.*, 1986). Liv.52 could correct the disturbed activity of alkaline phosphatase following CdCl<sub>2</sub> ingestion in mice (Rathore and Varma, 1986).

Cadmium also causes uncoupling of oxidative phosphorylation (Jacobs, 1956; Sport *et al.*, 1969), which inhibits intestinal absorption of nutrients like L-amino acids and D-Glucose (Kojima *et al.*, 1986). Further cadmium affects mitochondrial cytochrome oxidase and succinate (Prasad *et al.*; 1983). Cd also inhibits ATPase activity (Cross *et al.*, 1970). On the other hand, Liv.52 stimulates activities of mitochondrial cytochrome-c-oxidase, succinate and ATPase (Saxena and Garg, 1979; Bardhan *et al.*, 1985). This property can also prevent cell death.

Lastly cadmium is known to damage DNA (Rathore and Swarup, 1981) and lower RNA and protein contents (Gantayat and Patnaik; 1975). But it has been reported that Liv.52 could maintain normal amounts of microsomal protein. RNA and DNA, which were significantly lowered following carbon tetrachloride, induced hepatic insult (Subbarao and Gupta 1978).

## ACKNOWLEDGEMENT

While the Head of the School of Studies in Zoology gave department facilities, The Himalaya drug Company, Bombay gave other facilities for carrying out this investigation.

## REFERENCES

1. Bardhan, P. Sharma, S.K. and Garg, N.L., *Ind. J. Med. Res.*, 1985, 82, 359-364.
2. Coleman, J.E. and Vallee, B.L., *J. Biol. Chem.*, 1960, 235-390.
3. Cross, C.E. Ibrahim, A.B. and Mustafa, M.G., *Environ, Res.* 1970, 3, 512-520.
4. Gantayat, S.C. and Patnaik, S.K., *Curr. Sci.*, 1975, 44, 890-891.
5. Garty, M. Williams, M.B. and Klaassen, K.D. *Toxicology* 1986, 42, 111-119.
6. Hoffman, E.D. , Cook, J.A., Dilnzoio, N.R. and Coover, J.A., *Lab, Invest.*, 1975, 37, 655-664.
7. Jacobs, E.E. *J. Biol, Chem.* 1956, 223, 147-150.
8. Kaur, J., Biochemical studies on the Cadmium Stlenium interaction in rats. Ph.D. Thesis, P.G.I.M.E.R. Chandigarh, India, 1982.
9. Kinter, W.B. and Pritchard, J.B., In *Handbook of Physiology Section 9 – Reactions to environmental agents*. Eds. Lee, D.H.K. Falk H.L. Murphy, S.D. and Geiger, S.R. Williams, Baltimore, 1977: 563-573.
10. Kojime, S., Kiyozumi, M., Honda, T., Shimizu, T., Moriyama, Y. and Eishi, E. *Chem. Pharm. Bull.*, 1986, 34, 372-377.
11. Nath, R., *Environmental Pollution of Cd: Biological, Physiological and Health Effects*, Interprint, New Delhi (1986): p.11.
12. Nordberg, G., Friberg, L. and Piscator M. In. *Cadmium in the environment*, IInd edition, CRC Press, Cleveland Ohio 1971, 30-34.
13. Phillpotts, J.C. and Tyldesley, F.W., *Toxicol, Letters* 1986, 34, 271-275.
14. Piscator M. and Axelsson, B. *Arch. Env. Hlth.*, 1970, 21, 604-608.
15. Prasad, G.C. *J. Res., Ind. Med. Yoga & Homeo.*, 1976, 4, 38-43.
16. Prasad, P.V.V., Sridhar, M.K.C. and Desalu, A. B.O., *Arch, Env. Cont. Toxicol*, 1983, 12, 293-297.
17. Rathore, H.S., *Indian Drugs* 1986, 25 (1) , 7-10.
18. Rathore, H.S. and Varma, Rita, *Indian Drugs*, 1986, 25 (1), 11-18.
19. Rathore, H.S., and Swaruop, H., *Ind., J, Env. Stud. (London)* 1981, 19, 209-214.
20. Rathore, H.S. and Nandi, K.K., Under Publication 1988.

21. Richardson, M.E. and Fox, M.R., *Lab Invest*, 1974, 31, 722-731.
22. Riihimaki, V., *Work Environ*, IIIth, 1972, 9, 91-101.
23. Saini, M.R., Kumar, S. and Jagetia, G.C., *Indian Drugs* 1984, 9, 374.
24. Saini, M.R., Kumar, S., Devi, Uma and Saini, N., *Radiobiol, Radiother.* 1985, 26 (1), 487-490.
25. Sastri, K.V. and Subbadra, K., *Environ, Res.* 1985, 36, 32-54.
26. Saxena, A. and Garg, N.K. *Ind. J. Exp. Biol.* 1979.
27. Saxena, A., Sharma, S.K. and Garg, N.K., *Ind. J. Exp. Biol.* 1980, 11, 1330.
28. Sporn, A., Dinu, I., Stoensea, L. and Cirstea, A., *Nahrung* 1969, 13, 461-469.
29. Stazey, N.H. and Klaassen, C.D., *J. Toxicol, Environ IIIth* 1981, 7, 149-158.
30. Subbarao, V.V. and Gupta, M.L., *Ind. Practit.* 1978, 31, 831-834.
31. Teare, F.W., Jasansky, P. and Renaud, P.R., *Toxicol, Appl.* 1976, 41, 57-65.
32. Tripathi, S.N., Mishra, A.K., Upadhyaya, K.N., Dixit, O.P. and Srivastava, S.K. *J. Res. Ind. Med. Yoga & Homeo*, 1977, 1, 49.
33. Valberg, L.S. Haist, J. Cherian, M.G., Richardson L. and Gojer, R.A. *J. Toxicol, Environ, IIIth* 1977, 1, 1055-1066.
34. Wacker, W.E.C. *Fed. Proc.* 1970, 29, 1462-1468.