

Therapeutic Effects of Liv.52 in Post-Necrotic Hepatitis

Prof. Gupta, S., *F.R.C.P., D.C.H.*, Head of the Department of Pediatrics, Gastroenterology Unit,

Khatri, R.L., *D.C.H.*, Resident Medical Officer, Pediatrics, and

Srivastava, G., *M.D.*, Pediatrician.

Maulana Azad Medical College, New Delhi, India.

Infectious hepatitis is encountered in paediatric practice either during an epidemic or as sporadic cases. Clinically it may present in mild, moderate or severe forms. Varying degrees of destruction of the liver cells, degeneration, necrosis, autolysis have been reported chiefly in the centre of the lobule. Damage is limited to hepatic cells and does not involve the reticulum stroma, portal canals or intralobular vasculature. The lesion is widespread and diffuse in the whole parenchyma of the liver.

The liver has manifold functions and is intimately connected with various metabolic processes closely connected with growth and development. Its proper functioning has a great effect on the physiological functioning of the whole body. Hepatic injury leads to derangement of its functions. The liver has great reserve powers and also powers of regeneration; this being so, it is very difficult to correlate the clinical findings with biochemical and laboratory tests and even biopsy studies to determine the degree and extent of liver damage.

Aspiration biopsy studies of the liver offer a very reliable and certain method of assessing the structural and histopathological changes in the liver during the progress of the disease and it can also indicate the effects of therapy. A needle biopsy specimen, though small in size, can pick up a large number of pathological conditions as it gives the correct cytological picture and changes therein, especially in a disease like infectious hepatitis which is characterised by diffuse and widespread lesions.

Hepatic cells function in a constant state of portal anoxia and their characteristic reaction is necrosis, the extent of which depends on the nature of the injury. The condition may advance rapidly to hepatocellular failure, or may gradually show a picture of mild or moderate cirrhosis of liver.

The present paper reports a study of two patients suffering from infectious hepatitis who were treated and followed up for a year and a half each. Clinical, biochemical and laboratory studies were repeatedly carried out and the transthoracic needle biopsy study was done before and after the therapy. The findings are presented below:

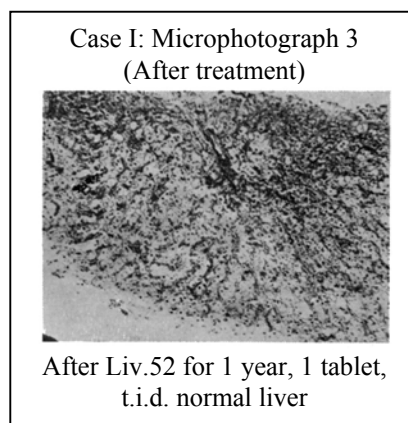
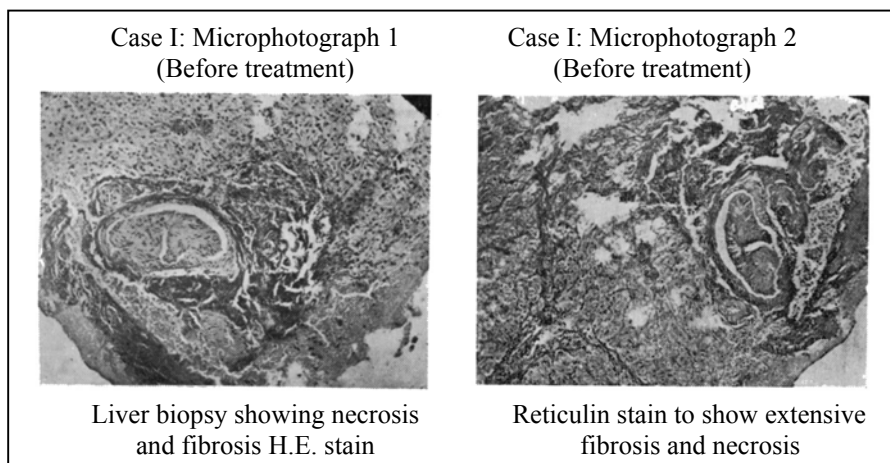
Case I :

A.S., three-year-old male, came with fever and jaundice for 10 days. Diagnosis of infectious hepatitis was made. he was put on supportive therapy, but his condition deteriorated and he was admitted after 10 days with a diagnosis of subacute hepatitis and impending coma. On admission, his serum bilirubin was 4.6 gm%. Total blood proteins 6.5 gm%, serum albumin being 4.3 gm% and serum globulin 2.3 gm%. S.G.O.T. was 140 units ml. and S.G.P.T. 123 units ml., Prothrombin time 26 seconds, urobilinogen was present in urine and stools were clay coloured. The child was put on steroids and other supportive measures. Steroids were gradually tapered off after six weeks of therapy. He recovered on this regimen and was discharged after one month's stay in the hospital. At this time his liver was soft and 6 cm below costal margin in the midclavicular line and spleen 3 cm below the costal margin. Liv.52 tablets were given, one tablet t.i.d., after stopping the steroids.

He was called for laboratory studies and liver biopsy after a period of four months after his discharge from the hospital. The findings were serum bilirubin 0.6 mg%, total proteins 7.2 gm%, serum albumin 4.3 gm%, serum globulin 2.9 gm%, S.G.O.T. 36 units/ml, S.G.P.T. 30 units/ml prothrombin time 20

seconds (control 15 sec.), liver was soft and measured 3 cm below the costal margin in the midclavicular line and the spleen 1 cm below the left costal margin showing marked regression in the size of both the organs.

Liver biopsy showed a post-necrotic cirrhosis on histopathological examination (*Microphotographs 1 and 2*). Liv.52 therapy was continued for almost 10 months. His liver became soft and spleen was just palpable. His clinical condition improved remarkably. Repeat liver biopsy was performed after one year of Liv.52 and the histopathological studies of the biopsy material revealed normal liver structure. (*Microphotograph 3*). He is under continuous observation till today.



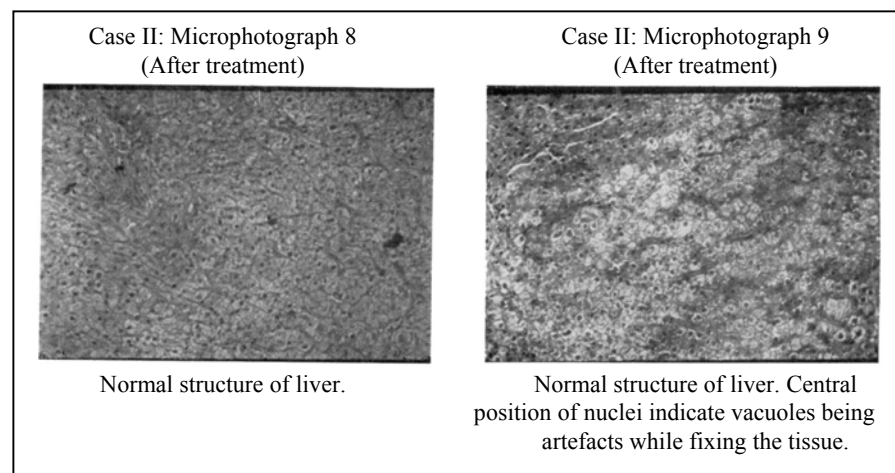

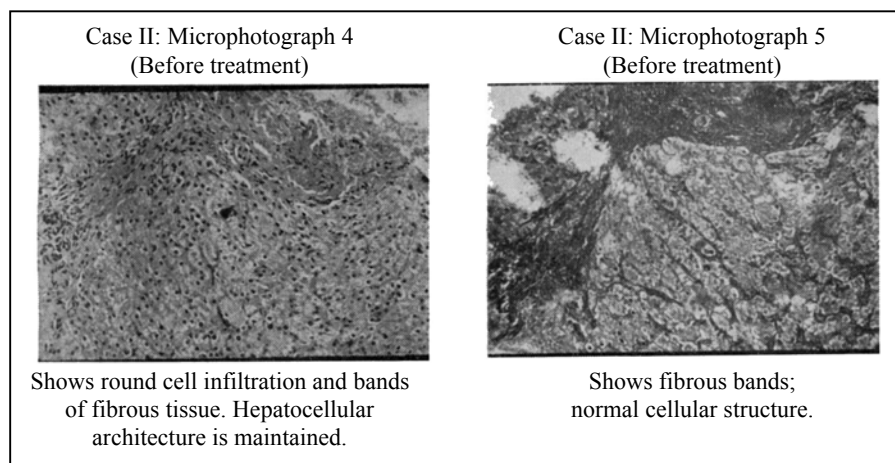
Case II:

Varsha, eleven-year-old girl, was admitted with a provisional diagnosis of post-hepatitis cirrhosis. She gave a history of distension of abdomen for 3 months. Oedema of feet for one month, anorexia for one month, yellow colour of urine for two weeks and occasional vomiting. There was no history of having taken drugs or of a bleeding tendency. There was a history of jaundice – 18 days' duration – three months ago. She was moderately nourished, with pallor and icterus and generalised anasarca. There was no cyanosis or dyspnoea. The liver was 4 cm palpable in the mid-clavicular line, firm to the feel but not tender. The spleen was 4.5 cm, palpable and firm. Blood showed haemoglobin 8 gm%, total white cell count 7600, polymorph 64%, lymphocytes 32%, large monocytes 3%, eosinophils 1%, urine showed bile pigments. Serum bilirubin 4.8 mg%, zinc sulphate turbidity 8 units. Prothrombin time 36 seconds, S.G.O.T. 128 units, S.G.P.T. 142 units, total blood proteins 6.4 gm%, albumin 2.6 gm%, globulin 3.8 gm%, ascitic fluid proteins 1.8 gm%.

The child was treated with routine treatment along with Prednisolone 2 mg/kg/day and Liv.52, 2 tablets t.i.d. for six weeks. After six weeks, icterus decreased considerably, ascites disappeared, the liver and the spleen regressed to 2 cm and there was marked improvement of appetite. Prednisolone was gradually tapered off and stopped after a total period of three months of therapy. Liver function tests at this stage (after three months) were normal but liver biopsy revealed post-necrotic cirrhosis. (*Microphotographs 4-7*). The liver was just palpable and the spleen not palpable. There was weight gain of 2 kg.

The child was subsequently given Liv.52 tablets for two years after initial admission and the liver and spleen at the last observation were not palpable. The patient was followed up in liver clinic and

was given 2 tablets of Liv.52 t.i.d. and the liver biopsy and revealed normal hepatic parenchyma. (*Microphotographs 8-9*).



DISCUSSION

Hepatic damage is a difficult condition to treat. The liver has great reserves and a good power of regeneration. Subacute hepatitis is one of those conditions in which there is no standard line of treatment which can be said to reverse the condition. In a few cases, some degree of clinical and biochemical and laboratory improvement may be noted after some time but in the majority of them hepatic failure, coma or other complication may bring about death. It would be the ambition of every clinician and research worker to have a drug that would help this difficult and trying malady and save the unfortunate victims from the ravages and complications of this disease.

In the first case steroids were administered along with Liv.52 for a period of four months. Steroids do not have a delayed or cumulative therapeutic effect. The effect of its therapy lasts only during the period of administration. The liver

biopsy done after four months of the cessation of corticosteroid therapy showed post-necrotic changes (*Microphotograph No. 2*) but on subsequent continuation of Liv.52 alone for six months, the histopathological changes in the same liver regressed to normal (*Microphotograph No. 3*). Infectious hepatitis is characterised by diffuse, well spread, generalised affection of the liver and hence one could not imagine or envisage the possibility of accidentally finding a normal liver strip in the needle biopsy. The liver also became less firm and regressed in size along with the spleen. The clinical, biochemical and histopathological findings are very significant and noteworthy, unparalleled in reports or observations.

In case two, although the child showed good clinical and biochemical response to combined corticosteroid and Liv.52 therapy for three months, the histopathological picture showed post-necrotic cirrhosis (*Microphotographs* Nos. 6 and 7). Continued, prolonged therapy with Liv.52 alone for 10 months showed completely normal hepatic parenchyma on needle biopsy (*Microphotograph* Nos. 8 and 9) and marked clinical improvement with regression of both the liver and spleen.

In both these cases continued therapy with Liv.52 alone helped the hepatic parenchyma to regain its physiological function, improve the laboratory response to the tests and revert the chronically inflamed hepatic cells parenchyma to a completely normal condition, as could be seen from the critical studies of the microphotographs of the biopsy material.

SUMMARY

1. Two cases of post-necrotic hepatitis are reported.
2. Earlier clinical response to corticosteroid therapy is observed but no change is observed in the histopathological picture.
3. Prolonged, continued use of Liv.52 helped the hepatic parenchyma to revert to normal architecture and the hepatic function tests to revert to normal.
4. Liv.52 tablets, administered for a prolonged time helped the regeneration of the hepatic structure and improvement of hepatic function.

REFERENCES

1. Gupta, S. *et al.*, (1972) Therapy of Infectious Hepatitis and Other Liver Disorders, *Probe*, 2, 93.
2. Mukerjee, A.B. and Dasgupta, M.: (1971) Cirrhosis of Liver – Results of Treatment with an Indigenous Drug : Liv.52, *Journal of the Indian Medical Profession*, 17, 7853.
3. Mukerjee, A.B. and Dasgupta, M. : (1970) Treatment of Viral Hepatitis by an Indigenous Drug – Liv.52, *The Indian Practitioner*, 6, 357.
4. Prasad, Lala Surajnandan, *et al* : (1971) Long-term Studies on the Therapy Hepatic Damage and Cirrhosis of Liver, *Current Medical Practice*, 12, 1071.